



**PATIENT**

Zelda Chittendan

**PRESENTING CLINICAL SIGNS**

History: Grade 4/6 heart Murmur, enlarged liver. Persistent cough since about April 2021.  
 -Pertinent abnormal PE/Chem/CBC/UA Results: ALT 156 (has been high in past), ALP 1091 (has been high in past), Na:K ratio 26; usually higher (in past 31 & 35). Radiographs attached separately.  
 -Sedation used: Sedation not required for scan.  
 -STAT: requested

**SPECIES**

Canine

**BREED**

Mix

**SEX**

Female Spayed

**ECHOCARDIOGRAM FINDINGS** \*Standing scan performed due to instability.

2D, m-mode, color flow and doppler imaging is available. The mitral valve is diffusely thickened with minimal prolapse into the left atrial lumen. There is severe eccentric mitral regurgitation present. The MR velocity is normal. There is severe left atrial enlargement. There is mild left ventricular dilation and increased sphericity indicative of volume overload. Left ventricular systolic function is hyperdynamic. There is normal systolic flow velocity across the aortic valve. The aortic valve appears trileaflet with normal mobility. No AI. The main pulmonary artery is mildly dilated. Normal pulmonic outflow velocity with laminar profile. No pulmonic insufficiency. Moderate right atrial and right ventricular dilation. The tricuspid valve is mildly with moderate tricuspid regurgitation. The tricuspid regurgitant velocity is elevated, indicative of severe pulmonary hypertension (PG 80mmHg). Scant pericardial effusion. No obvious pleural effusion. No obvious ascites. No cardiac masses are seen.

**AGE**

13 years

**CARDIAC CHART**

**WEIGHT**

29.7

**INTERPRETED BY**

Maggie Machen  
 Lamy, DVM, DACVIM  
 (Cardiology)

CANINE CARDIAC PARAMETERS	MR VMAX (m/s)	TR VMAX (m/s)	LA/AO (Boon method)	LA/AO (Heart Base; Swe)	FS (%)	EF (%)	EPSS (cm)
NORMAL PARAMETER	4.5-5.5	<2.7	1.3	<1.6	28-40	40-100	<0.6
PATIENT	4.6	4.2		>2	31	58	
CANINE CARDIAC PARAMETERS	HR (BPM)	AV VMAX (m/s)	PV MAX (m/s)	BODY WEIGHT (kg)	LA 2D short axis Base view (cm)	LVIDd Avg; 2D and m-mode short axis (cm)	LVIDs Avg; 2D and m-mode short axis (cm)
NORMAL PARAMETER	50-100	0.7-1.7	0.7-1.6	BELOW	BELOW	BELOW	BELOW
PATIENT	170	NM	0.4	13.45		4.3	3.0
*Normal chamber parameters expressed as a mean value (SD)				3	1.27 (5.3)	2.46 (2.46)	1.36 (5.5)
BODY WEIGHT DEPENDENT PARAMETERS				5	1.40 (4.5)	2.74 (5.2)	1.60 (4.7)
*Note: All measurements based upon multi-modal images and methods. An average value is reported.  Adapted from June Boon, Veterinary Echocardiography, 1998 Rishniw M and Hollis NE, J Vet Intern Med 2000; 14:429-435 Hansson et al, Vet Rad and Ultrasound 2002 Bonagura et al. Echocardiography: principles of interpretation, Vet Clin North Am 15:1177, 1995				10	1.50 (3.8)	3.27 (3.5)	2.06 (3.1)
				15	1.83 (2.0)	3.71 (2.4)	2.43 (2.1)
				20	2.02 (1.9)	4.14 (2.2)	2.80 (2.0)
				25	2.18 (2.4)	4.48 (2.9)	3.10 (2.5)
				30	2.33 (3.3)	4.83 (3.9)	3.39 (3.4)
				35	2.48 (4.3)	5.17 (5.0)	3.69 (4.5)
				40	2.62 (5.2)	5.48 (6.1)	3.96 (5.4)
				50	2.88 (7.1)	6.07 (8.3)	4.46 (7.4)

**HOSPITAL NAME**

White Marsh Animal  
 Hospital

**REFERRING VET**

Dr. Danna

**INVOICE**

21561

**DATE**

10/18/21

## INTERPRETATION OF THE FINDINGS & FURTHER RECOMMENDATIONS

Chronic degenerative valve disease causing severe mitral and mild to moderate tricuspid regurgitation. Batrial and ventricular enlargement in addition to severe MR/TR and pulmonary hypertension indicates the risk for spontaneous congestive heart failure is high. Scant pericardial effusion/liver congestion is concerning for early right-sided congestion, and full cardiac support is recommended including sildenafil therapy. If the patient appears unstable, highly recommend overnight hospitalization for supportive care at a 24-hour facility. Additionally cough suppression may be useful in the face of normal breathing rates in the future.

Unfortunately, with this degree of heart disease and congestion, the prognosis is guarded to poor with an average survival time of 6-12mo at this point. Most dogs are able to maintain a good quality of life for some time however with medications. Going forward, patient will remain at high risk for recurrent CHF (left or right sided), collapse episodes and/or development of malignant arrhythmias/sudden death in the future.

Omega fatty acid supplementation and mild salt restriction may also be of some long-term benefit once stabilized. Monitor for development of a cough, labored breathing, exercise intolerance or collapse episodes. Monitoring of sleeping breathing rates is recommended as the best way to screen for improvement/recurrent CHF at home.

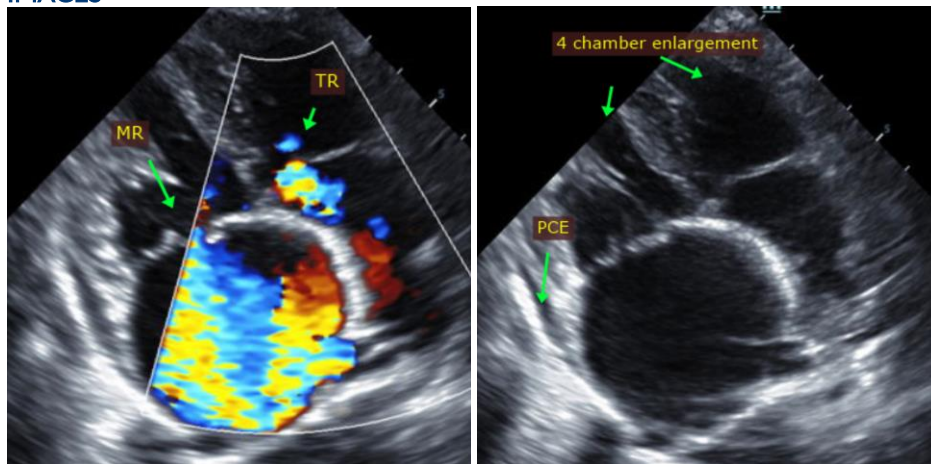
## PLAN

Recommend hospitalization for stabilization. Institute sildenafil 1-2mg/kg PO q12h. Institute spironolactone 1-2mg/kg PO q12h. Institute Pimobendan 0.3mg/kg PO q12h. Institute furosemide 1-2mg/kg PO q12h. Hydrocodone as needed for cough suppression.

Recheck renal panel and BP in 1-2 weeks, then every 3-4 months lifelong. If doing well and BP is >130mmHg, institute ACE-I 0.5mg/kg PO q12h.

A recheck echocardiogram is recommended in 6 months to screen for progression, sooner if clinical signs arise.

## IMAGES



The information and recommendations provided are based on the images presented by the referring veterinarian. No evaluation can be communicated regarding pathology that was not visible in the image/video clips provided.

Thank you for this referral. This report was generated using transcription software, and minor dictation errors may be present. If the clinical or image interpretation does not parallel your findings or if I can be of any further assistance, please contact me.

**Maggie Machen Lamy, DVM**  
Diplomate of the American College of Veterinary Internal Medicine (Cardiology)  
Email: [info@sonopath.com](mailto:info@sonopath.com)